

Acute Stroke: A Case Study of a “Not-So-Uncommon” Cause of Ischemic Stroke in Young People

Kathleen MacKerrow, RN, MS, GCNS
Stroke Program Coordinator
Geriatric Clinical Nurse Specialist
Mills-Peninsula Health Services
mackerk1@sutterhealth.org
(650) 696-7681

Presentation and Assessment of Acute Stroke

- 48-old-male mechanic presents via car to the Peninsula Medical Center Emergency Department after experiencing sudden acute neurological change at 0820 while driving with his family members (i.e., left upper/lower extremity weakness, dark visual spot in right eye, right next pain, right facial numbness). Patient reports feeling fine over the past few days, in fact he completed a “lot of housework” over the weekend, however noticed a “swishing” noise in his right ear yesterday.
- PMH: “borderline” hypertension, hypothyroidism
- Medications: Levothyroxine, multivitamins
- Upon arrival to ED;
 - VS: BP 160/98, P 88, R 20, T 98.2, wt 101 kg, ht 5’11”
 - NIH Stroke Scale (4) : 1(facial droop), 1 (LUE), 1 (LLE), 1 (facial numbness).
 - Additional neurological findings; waxing and waning dark spot in right visual field (right eye only), observed Horner’s syndrome.

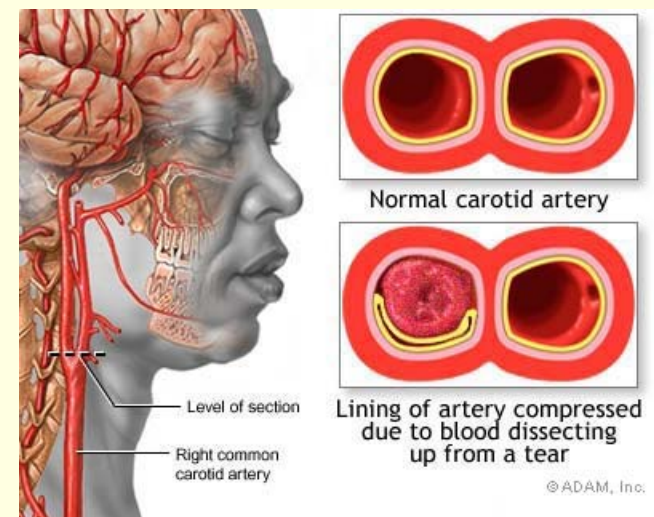


Acute Work-Up

- Immediate stroke alert activated by triage RN upon arrival
- Interventions; IV line established, cardiac monitoring (NSR with positional tachycardia when upright), reassessment of NIH Stroke Scale, permissive HTN allowed until CT result
- Diagnostics; Non-contrast CT (completed within 14 minutes of arrival), portable CXR (completed within 32 minutes of arrival), labs-CBC, chemistry panel, PT/INR/PTT, UA, Trop-I (completed within 29 minutes of arrival)
- NIH Stroke Scale worsening (6); 2 (LUE), 2(LLE), 1(facial droop), 1 (facial numbness)
 - Fluctuating visual loss to right eye, increased headache pain and right neck pain. Continued Horner's syndrome to right eye.
- CT negative for bleeding or acute ischemic changes.
- No known contraindications to IV-t-PA
- Patient and family consent for t-PA and administered within 56 minutes of arrival.
 - Diagnosis: Suspected evolving ischemic stroke.

Diagnosis, Hospital Course, Outcome

- Right internal carotid artery dissection with right MCA ischemic stroke. No hemorrhage or aneurysm formation afterwards.
 - Cause: Likely HTN combined with strenuous activity (moving heavy furniture in the days prior to stroke)
- Clotting disorder work-up negative
- No suspected connective tissue disease
- Started on antihypertensive treatment
- No other risk factors identified during hospitalization
- Placed on 6 months anticoagulation and activity restriction, then aspirin thereafter
- Beta-blocker for intermittent tachycardia
 - Likely from carotid sinus baroreceptor damage
- Resolving neurological deficits; PT, OT, SLP evaluations and treatment received
- Discharge status:
 - Home, ambulatory with cane
 - Right arm weakness resolved after outpatient OT treatments
 - Returned to work in 3 months



Arterial Dissections: Take Home Points

- Occurs more frequently than was once thought
 - Carotid artery
 - Vertebral artery
 - Basilar artery
 - Intracranial and/or extracranial
- Frequency:
 - Account for 1-2.5% of ischemic strokes in the general population
 - Account for 5-20% of strokes in those younger than 45-y-old
 - Improving imaging techniques to diagnose
- Spontaneous or trauma-related
 - Risk factors; connective tissue/collagen diseases, hypertension, traumatic neck injuries (choking, punched, whiplash/MVAs, coughing/sneezing/vomiting, neck manipulations)
- Unique symptom assessment;
 - Red flag with neck pain, scalp pain or head pain
 - Horner's syndrome, cranial nerve palsies
 - 25% cases pulsatile tinnitus or "subjective" bruit
- Discussion

