

Shock

For patients with poor perfusion not rapidly responsive to IV fluids

History

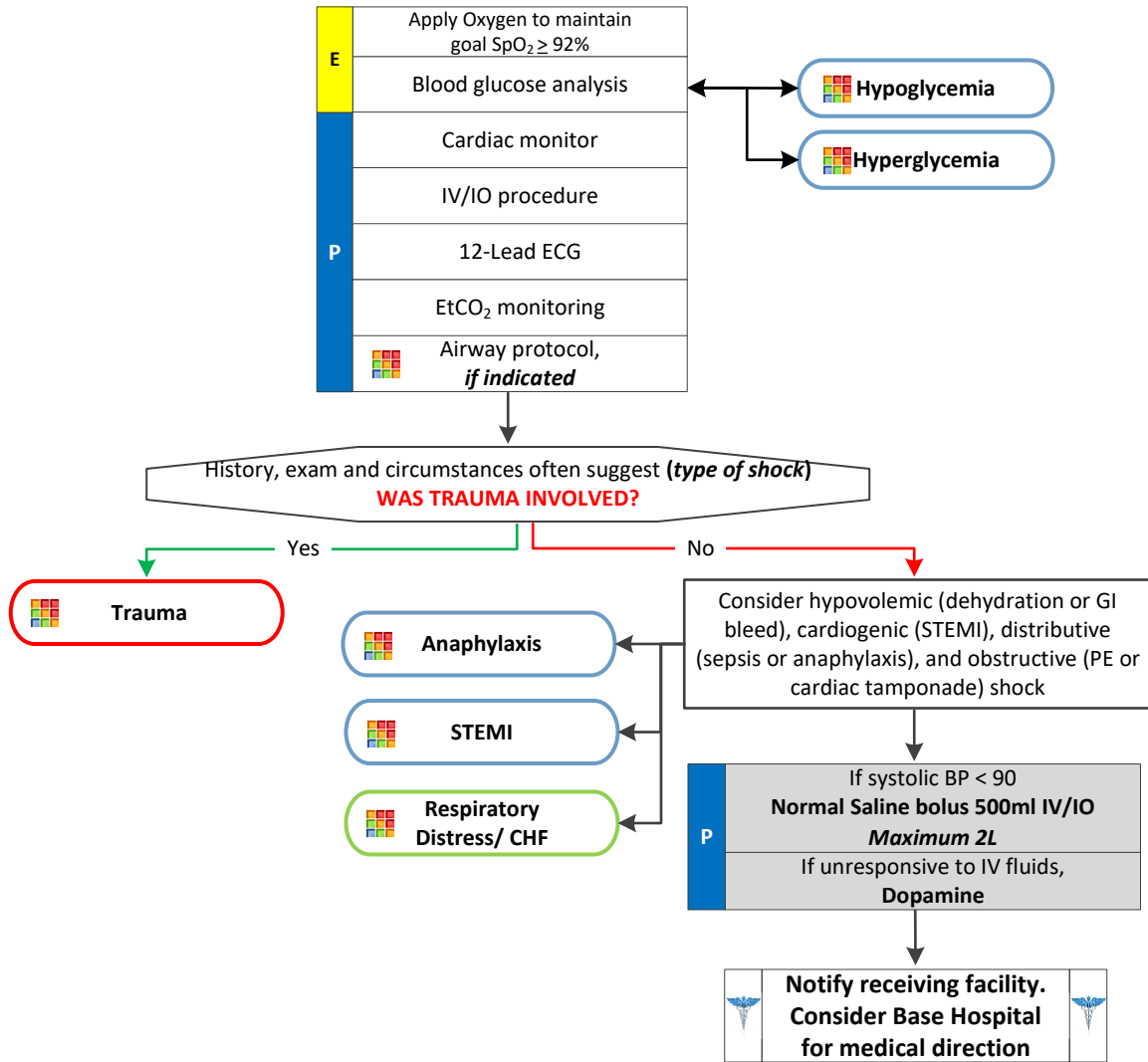
- Blood loss (amount?)
- Fluid loss (vomiting, diarrhea or fever)
- Infection (e.g., UTI, cellulitis, etc.)
- Cardiac ischemia
- Medications
- Allergic reaction
- Pregnancy
- History of poor oral intake

Signs and Symptoms

- Restlessness or confusion
- Weakness or dizziness
- Weak, rapid pulse
- Pale, cool, clammy skin signs
- Delayed capillary refill
- Hypotension
- Coffee-ground emesis
- Tarry stools

Differential

- Shock (hypovolemic, cardiogenic, septic, neurogenic or anaphylaxis)
- Ectopic pregnancy
- Cardiac dysrhythmias
- Pulmonary embolus
- Tension pneumothorax
- Medication effect or overdose
- Vasovagal effect
- Physiologic (pregnancy)



Shock

For patients with poor perfusion not rapidly responsive to IV fluids

Pearls

- Hypotension can be defined as a systolic blood pressure of less than 90mmHg. This is not always reliable and should be interpreted in context with the patient's typical BP, if known. Shock may be present with a seemingly normal blood pressure initially.
- Shock is often present with normal vital signs and may develop insidiously. Tachycardia may be the only manifestation.
- Beta blockers and other blood pressure medications can mask tachycardia and skin signs.
- For patients with suspected cardiogenic shock who are not responsive to an initial fluid bolus, limit additional IV fluids and avoid Dopamine. Contact Base Hospital for medical direction.
- Consider all causes of shock and treat per appropriate Treatment Protocol.
- Hypovolemic shock:
 - Hemorrhage, trauma, GI bleeding, ruptured abdominal aortic aneurysm (AAA), or pregnancy-related bleeding. For suspected AAA, consider immediate transport to the closest trauma center.
- Cardiogenic shock:
 - Heart failure, MI, cardiomyopathy, myocardial contusion, ruptured ventricle/septum/valve or toxins.
- Distributive shock:
 - Sepsis, anaphylactic, neurogenic, or toxins.
 - Neurogenic shock generally presents with warm, dry, and pink skin with normal capillary refill time; patient typically alert.
- Obstructive shock:
 - Pericardial tamponade, pulmonary embolus (PE), or tension pneumothorax.
 - Signs may include hypotension with distended neck veins, tachycardia, unilateral decreased breath sounds or muffled heart tones.

